

Knee Osteoarthritis follow-up after Platelet-rich plasma (PRP) treatment with Vitrea

Abstract

With aging population, the rise of obesity or growing interest in sport, the frequency of degenerative cartilage pathologies is increasing.

Except for Osteochondritis, cartilage pathologies always begin with the superficial surface layer and then extend to the depths in the cartilage matrix.

There are several cartilage gradation systems such as ICRS (International Cartilage Repair Society) or WORMS system in MRI (both available in Vitrea) (Figure 1.).

Knee Osteoarthritis (OA) is a chronic joint disease, characterized by progressive destruction of joint cartilage, leading to pain and loss of function. This pathology affects more than 39 million people in Europe and this figure will probably double by 2020 (Figure 2.).

There are three stages of Osteoarthritis:

- early stage: joint cartilage degeneration occurs,
- intermediate stage: onset of the first radiological signs,
- advanced stage: full-thickness loss of cartilage and joint cartilage has disappeared.

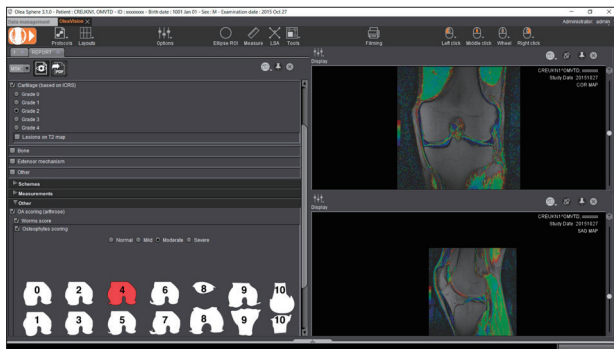


Figure 1

Degenerative osteoarthritis is a chronic mechanical disease that differs from inflammatory osteoarthritis, which is an acute inflammatory disease.

Diagnosis and treatments are different.

Plate let-rich plasma (PRP) is a blood derivative product.

The PRP is collected from blood and isolated by centrifugation. There is no risk of "rejection" or allergy since blood is drawn from the patient (autologous). Patient's own platelet that has growth and healing factors are used.

Complications

- Pain
- Functional disability (extended work leave and decreased quality of life)
- Joint infection
- Osteonecrosis
- Cardiovascular risk

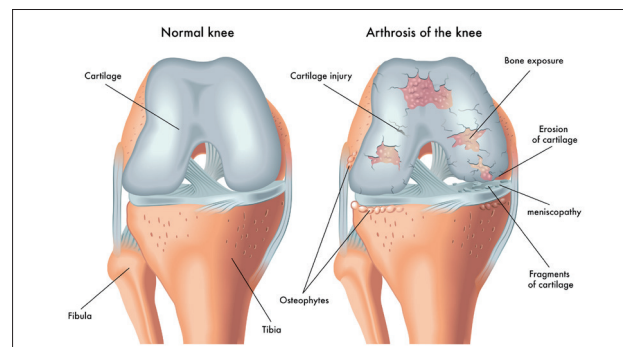


Figure 2

Therapeutic options

- Treatment of degenerative cartilage pathologies will be carried out by pain management and/or functional repercussions
- Rest
- Weight loss
- Physiotherapy
- Medical treatment
- Orthopedic biology, an emerging technique including injections of PRP to induce regeneration
- Surgery (arthroscopy, single or multi-compartment prosthesis)

The interest of knee cartilage T2 mapping has been documented in various publications and this technique is a hot topic of clinical and research studies. The cartilage application in Vitrea can be used for that purpose.

To assess the response to PRP injection treatment, regions of interest (ROI) can be selected on different areas of cartilage (Figure 3.).

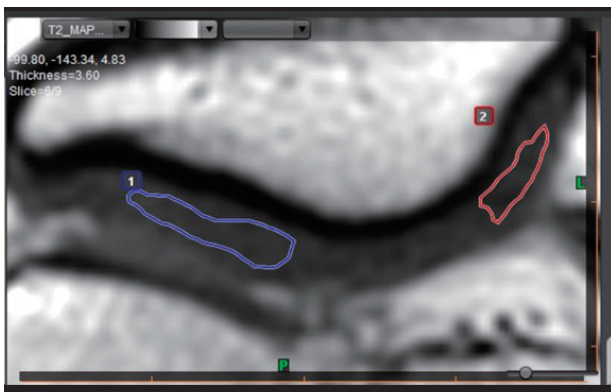


Figure 3

Then the threshold filtering function is used to select the suitable threshold values in ms (from 10 to 38 ms according to publications¹⁻¹⁹ resulting cartilage volume can be then evaluated.) (Figure 4/A.).

Comparing the current results with those prior to PRP injection make it easier to follow-up T2 values progression and the resulting cartilage volume (Figure 4/B.).

Addition

Texture is an emerging graphic representation criterion in medical imaging, particularly for cartilage. Thus, the distribution of T2 values within an MRI slice can be quantified by the gray-level co-occurrence matrix.

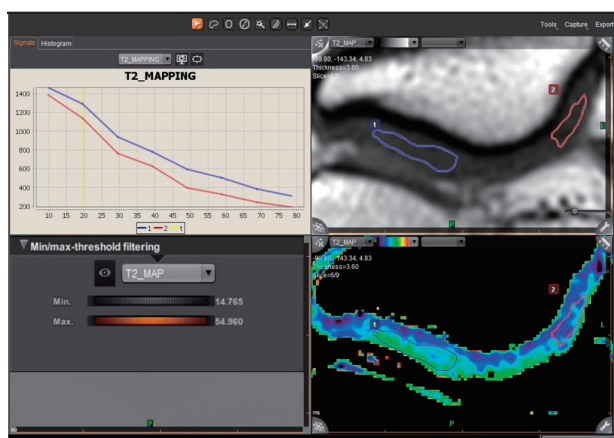
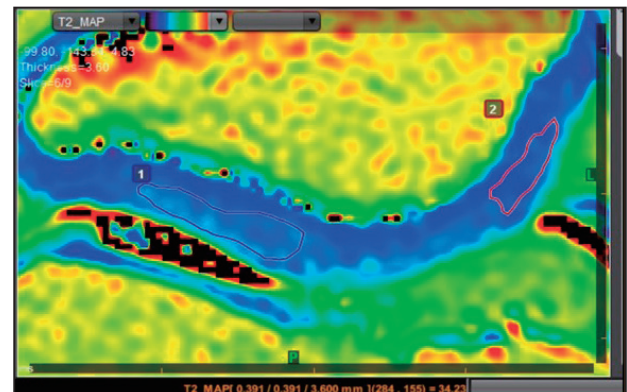


Figure 4/A

Figure 4/B

Reference

1. Ebert JR, Robertson WB, Woodhouse J, Fallon M, Zheng MH, Ackland T, et al. Clinical and magnetic resonance imaging-based outcomes to 5 years after matrix-induced autologous chondrocyte implantation to address articular cartilage defects in the knee. *Am J Sports Med* 2011;39:753-63. Ref
2. Trattng S, Mamisch TC, Welsch GH, Glaser C, Szomolanyi P, Gebetsroither S, et al. Quantitative T2 mapping of matrix-associated autologous chondrocyte transplantation at 3 Tesla: an in vivo cross-sectional study. *Invest Radiol* 2007;42:442-8.
3. Eagle S, Potter HG, Koff MF. Morphologic and quantitative magnetic resonance imaging of knee articular cartilage for the assessment of post-traumatic osteoarthritis. *J Orthop Res* 2016.
4. Crema MD, Roemer FW, Marra MD, Burstein D, Gold GE, Eckstein F, et al. Articular cartilage in the knee: current MR imaging techniques and applications in clinical practice and research. *Radiographics* 2011;31:37-61.
5. <https://www.abovepain.com/conditions/knee-osteoarthritis.html>
6. http://www.prp.arthrose.bx33.fr/Prp_et_Arthrose.K.htm#Prp_et_Arthrose.K
7. http://www.prp.arthrose.bx33.fr/Prp_et_Arthrose.K.htm#Preparation_du_PRP_A
8. <https://www.spinemd.com/about-us/experience>
9. Plasma enrichi en plaquettes en pathologie musculosquelettique ; Benjamin Dallaudiere, Alain Silvestre, Herve Bard ; *Sauramps Medical*
10. Hyaluronic Acid, PRP/Growth Factors, and Stem Cells in the Treatment of Osteochondral Lesions ; Diana Ribeiro Pereira, Joana Silva-Correia, Elisaveta Kon, Helder Pereira, Piero Volpi, Joao Espregueira-Mendes, Rui L. Reis, and J. Miguel Oliveira ; *Injuries and Health Problems in Football*, DOI 10.1007/978-3-662-53924-8_57
11. Whole-Organ Magnetic Resonance Imaging Score (WORMS) of the knee in osteoarthritis ; C. G. Peterfy M.D. Ph.D., A. Guermazi M.D., S. Zaim M.D., P. F. J. Tirman M.D., Y. Miaux M.D., D. White Ph.D., M. Kothari Ph.D., Y. Lu Ph.D., K. Fye M.D., S. Zhao Ph.D. and H. K. Genant M.D. ; *OsteoArthritis and Cartilage* (2004) 12, 177.190
12. <https://www.cdc.gov/arthritis/basics/osteoarthritis.htm>
13. <https://www.mayoclinic.org/diseases-conditions/osteoarthritis/symptoms-causes/syc-20351925>
14. *Caspian J Intern Med* 2011; 2(2):205-212
15. <https://www.howardluksmd.com/sports-medicine/degenerative-joint-disease-treatments/>
16. Validity of T2 mapping sequences at 3T for the assessment of knee cartilage repair after treatment with platelet rich plasma (PRP) ; F. Bruno, S. Quarchioni, S. Mariani, F. Arrigoni, L. Patriarca, L. Zugaro, A. Barile, C. Masciocchi; *LAquila/IT* ; 10.1594/ecr2017/B-1158
17. Intra-articular Injection of Mesenchymal Stem Cells and Platelet-Rich Plasma to Treat Patellofemoral Osteoarthritis: Preliminary Results of a Long-Term Pilot Study ; Julien Pintat, MD, Alain Silvestre, MD, Guy Magalon, MD, PhD, Alain Pierre Gadeau, PhD, Lionel Pesquer, MD, Anne Perozziello, MD, Alain Peuchant, MD, Charbel Mounayer, MD, PhD, and Benjamin Dallaudiere, MD, PhD ; *J Vasc Interv Radiol* 2017; 1.6
18. A Reference Database of Cartilage 3 Tesla MRI T2 Values in Knees without Diagnostic Evidence of Cartilage Degeneration: Data from the Osteoarthritis Initiative ; Gabby B. Joseph, Charles E. McCulloch, Michael C. Nevitt, Ursula Heilmeyer, Lorenzo Nardo, John A. Lynch, Felix Liu, Thomas Baum, and Thomas M. Link ; *Osteoarthritis and Cartilage*. 2015 June ; 23(6): 897.905. doi:10.1016/j.joca.2015.02.006.
19. Texture analysis of cartilage T2 maps: individuals with risk factors for OA have higher and more heterogeneous knee cartilage MR T2 compared to normal controls - data from the osteoarthritis initiative ; Gabby B Joseph1*, Thomas Baum, Julio Carballido-Gamio, Lorenzo Nardo, Warapat Virayavanich, Hamza Alizai, John A Lynch, Charles E McCulloch, Sharmila Majumdar and Thomas M Link ; *Arthritis Research & Therapy* 2011, 13:R153

CANON MEDICAL SYSTEMS CORPORATION
<https://global.medical.canon>

©Canon Medical Systems Corporation 2018-2021. All rights reserved.
Design and specifications are subject to change without notice.
MOIH10002EAA 2021-10 CMSC/Produced in Japan

Canon Medical Systems Corporation meets internationally recognized standards for Quality Management System ISO 9001, ISO 13485.
Canon Medical Systems Corporation meets the Environmental Management System standard ISO 14001.

Made for Life is a trademark of Canon Medical Systems Corporation.
This document may include trademarks or registered trademarks of their respective owners.

The results in this document are the findings of the author.
Clinical outcomes may vary dependent upon clinical use and environment.

Made For life